GSC Biological and Pharmaceutical Sciences
eISSN: 2581-3250 CODEN (USA): GBPSC2
Cross Ref DOI: 10.30574/gscbps
Journal homepage: https://gscbps.gsconlinepress.com/

(CASE REPORT)

Check for updates

URINARY TRACT INFECTION CAUSED BY *SHIGELLA BOYDII* IN AN 84-YEAR-OLD WOMAN: A CASE REPORT AND REVIEW OF THE LITERATURE

Hamza Kachkouch [1, 3, *], Jinane Bari [2, 3], Fedwa Cherrafi [1, 3], Youssef Kamouni [1] and Lamiae Arsalane [1, 3]

[1] Laboratory of Microbiology, Avicenne Military Hospital, Marrakech, Morocco
[2] Laboratory of Microbiology, Ibn Tofail Hospital, Mohammed VI University Hospital Center, Marrakech, Morocco
[3] Faculty of Medicine and Pharmacy, Cadi Ayyad University, Marrakech, Morocco
* Corresponding Author: Hamza Kachkouch

ORCID Details
Hamza Kachkouch: https://orcid.org/0009-0004-0212-3853
Jinane Bari: https://orcid.org/0009-0007-5252-1579
Youssef Kamouni: https://orcid.org/0009-0002-6421-5185
Lamiae Arsalane: https://orcid.org/0000-0002-7964-2932

GSC Biological and Pharmaceutical Sciences, 2026, 37(02), 275–279

Publication history: Received on 14 October 2026; revised on 23 November 2026; accepted on 25 November 2026

Article DOI: https://doi.org/10.30574/gscbps.2026.37.2.0418

Copyright © 2026 Author(s) retain the copyright of this article. This article is published under the terms of the Creative Commons Attribution License 4.0

ABSTRACT

Background: *Shigella* species are well-known agents of bacillary dysentery, but extra-intestinal infections are uncommon, and urinary tract infections (UTIs) caused by *Shigella* are exceptional. Most published cases involve *Shigella sonnei* or *Shigella flexneri*; *Shigella boydii* has only rarely been reported as a urinary pathogen.

Case presentation: We report the case of an 84-year-old woman with a history of heart disease and thyroid dysfunction who presented to the emergency department with burning on urination and urinary frequency in a febrile context (temperature 39 °C). Urinalysis showed cloudy urine with leukocyturia and haematuria (10^4/mL each). Culture yielded a Gram-negative bacillus identified as *S. boydii* by the BD Phoenix M50 automated system (confidence value 99%). The isolate was resistant to fluoroquinolones (ciprofloxacin and levofloxacin) and susceptible to β-lactams, including ampicillin and third-generation cephalosporins, carbapenems, aminoglycosides, trimethoprim-sulfamethoxazole, fosfomycin and nitrofurantoin. Empirical therapy with a fluoroquinolone combined with an aminoglycoside was adjusted according to the antimicrobial susceptibility results, and the patient had a favourable outcome.

Conclusion: Although rare, *S. boydii* should be considered a potential uropathogen, particularly in elderly patients with comorbidities. Accurate identification, including serological confirmation to rule out inactive *Escherichia coli*, and systematic susceptibility testing are essential, as fluoroquinolone resistance—an increasing global concern in *Shigella*—may compromise standard empirical regimens.

Keywords: *Shigella boydii*; Urinary Tract Infection; Extra-Intestinal Shigellosis; Elderly; Fluoroquinolone Resistance; Case Report

1 INTRODUCTION

Shigella is a genus of non-motile, non-lactose-fermenting Gram-negative bacilli belonging to the family *Enterobacteriaceae*. The genus comprises four species, or serogroups: *S. dysenteriae* (group A), *S. flexneri* (group B), *S. boydii* (group C) and *S. sonnei* (group D) [1,2]. These organisms are responsible for shigellosis, an invasive inflammatory infection of the colon that remains a leading bacterial cause of diarrhoeal morbidity and mortality worldwide, particularly in low- and middle-income countries [1]. *S. boydii* is the least frequently isolated species overall and is found mainly in South Asia and parts of Africa; it is genetically heterogeneous, with at least 19 serotypes described [2,3].

Extra-intestinal manifestations of shigellosis are uncommon and include bacteraemia, reactive arthritis, neurological complications, vaginitis and, very rarely, urinary tract infection [4,5]. Since the first descriptions of urinary carriage of *S. sonnei* [6], only a limited number of symptomatic *Shigella* UTIs have been published, mostly in children with urinary tract abnormalities or in adults with predisposing conditions [7–10]. Cases caused by *S. boydii* are exceptional [11].

We report a case of febrile urinary tract infection caused by a fluoroquinolone-resistant *S. boydii* in an 84-year-old woman, and we review the diagnostic and therapeutic implications of this unusual presentation.

2 CASE PRESENTATION

An 84-year-old woman with a history of heart disease, followed in the endocrinology department for thyroid dysfunction, presented to the emergency department of Avicenne Military Hospital, Marrakech, in March 2024 with burning on urination and urinary frequency evolving in a febrile context.

On clinical examination, the patient was febrile at 39 °C.

A urine cytobacteriological examination was requested. A first-morning midstream urine sample was collected in a sterile container after discarding the first void. The urine was cloudy and yellow. Microscopic examination showed leukocytes at 10^4/mL and red blood cells at 10^4/mL. Culture yielded a pure growth of Gram-negative bacilli at a count of $\geq 10^5$ CFU/mL (Figure 1). Identification and antimicrobial susceptibility testing were performed with the BD Phoenix M50 automated system (BD Diagnostics, Sparks, MD, USA; panel UNMIC/ID-432), which identified the isolate as *Shigella boydii* with a confidence value of 99%. In accordance with the instrument's expert-system message, serological confirmation was recommended.

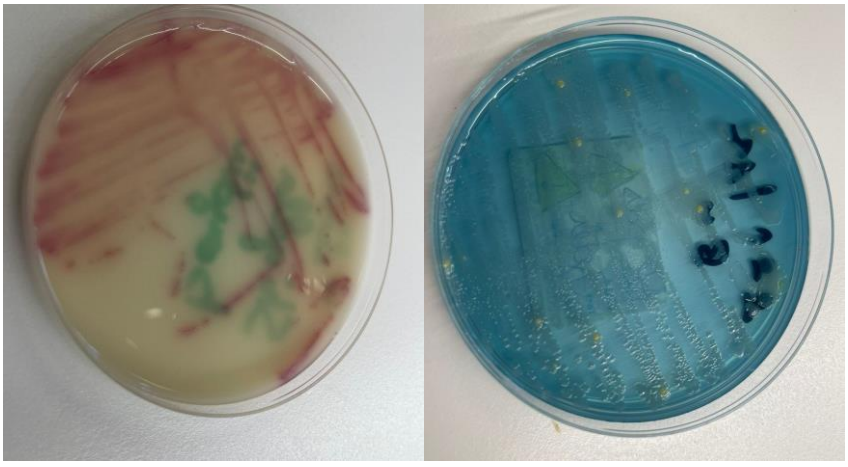

(A) (B)

Figure 1: Culture of the urine specimen. (A) Growth on chromogenic agar; (B) growth on bromothymol blue lactose agar showing lactose-non-fermenting colonies. The isolate was subsequently identified as *Shigella boydii* by the BD Phoenix M50 system.

Minimum inhibitory concentrations (MICs) and their interpretation are shown in Table 1. The isolate was resistant to ciprofloxacin (MIC >1 mg/L) and levofloxacin (MIC >4 mg/L), and susceptible to aminoglycosides, carbapenems, penicillins and cephalosporins tested, trimethoprim-sulfamethoxazole, fosfomycin and nitrofurantoin. There was no phenotypic evidence of extended-spectrum β-lactamase production.

Empirical antibiotic therapy combining a fluoroquinolone and an aminoglycoside had been started at admission. In view of the fluoroquinolone resistance, treatment was modified according to the antibiogram. The clinical course was favourable, with resolution of fever and urinary symptoms and a sterile control urine culture.

Table 1: Antimicrobial susceptibility profile of the *Shigella boydii* urinary isolate (BD Phoenix M50).

Antibiotic class	Antibiotic	MIC (mg/L)	Interpretation
Aminoglycosides	Amikacin	≤8	S
	Gentamicin	≤2	S
	Tobramycin	≤2	S
Carbapenems	Ertapenem	≤0.25	S
	Imipenem	1	S
	Meropenem	≤0.125	S
Penicillins	Ampicillin	≤4	S
	Amoxicillin-clavulanate	≤2/2	S
	Piperacillin-tazobactam	≤4/4	S
Cephalosporins	Cefazolin	≤4	S
	Cefixime	≤0.5	S
	Ceftazidime	≤2	S
	Ceftriaxone	≤1	S
Fluoroquinolones	Ciprofloxacin	>1	R
	Levofloxacin	>4	R
Others	Trimethoprim-sulfamethoxazole	≤2/38	S
	Fosfomycin (with G6P)	≤16	S
	Nitrofurantoin	≤32	S
	Tigecycline	≤1	—

MIC, minimum inhibitory concentration; S, susceptible; R, resistant; G6P, glucose-6-phosphate. Interpretation according to CA-SFM/EUCAST.

3 DISCUSSION

Shigella species are primarily enteric pathogens, and their isolation from urine is uncommon. In their classic review of extra-intestinal shigellosis, Barrett-Connor and Connor emphasised that dissemination beyond the intestinal mucosa is rare [4]. Urinary involvement was first described as asymptomatic bacteriuria in a chronic faecal carrier of *S. sonnei* [6], and subsequent reports have documented symptomatic infections, mostly due to *S. sonnei* and *S. flexneri* [7–10]. Karakaş et al. reported a small series of *Shigella* UTIs in adults, most of whom were elderly or had underlying conditions [10]. To our knowledge, *S. boydii* UTI has been reported only exceptionally; Erdiren et al. described a case in an 80-year-old woman presenting with dysuria and pollakiuria [11], a presentation strikingly similar to that of our patient. *S. boydii* has also been described as a cause of bacteraemia, notably in children [5].

3.1 Pathophysiology and risk factors

The most plausible route of infection is ascending contamination of the urinary tract from the perineal area by faecal flora, following symptomatic or asymptomatic intestinal carriage [6,7,10]. Unlike uropathogenic *E. coli*, which relies on adhesins such as type 1 and P fimbriae to colonise the uroepithelium [15], *Shigella* is primarily adapted to invasion of the colonic mucosa [2], which may partly explain the rarity of this localisation. Host factors therefore probably play a major role. In children, vesicoureteral reflux and other urinary tract abnormalities have been identified as predisposing factors [7,8], whereas in adults, advanced age, diabetes, urinary incontinence, immunosenescence and chronic comorbidities are frequently reported [10,15]. In our patient, advanced age and cardiac and endocrine comorbidities were likely contributing factors. The absence of a reported history of diarrhoea does not exclude intestinal carriage, as asymptomatic carriage has been documented in urinary cases [6]; a stool culture is therefore useful to identify the reservoir and to prevent secondary transmission.

3.2 Diagnostic considerations

Clinically, *Shigella* UTI is indistinguishable from UTI caused by more common uropathogens and presents with dysuria, frequency, suprapubic pain and, in upper tract involvement, fever [7,9,11]. The diagnosis is therefore exclusively microbiological. A major pitfall is the misidentification of *Shigella* and *E. coli*, which share 80–90% nucleotide similarity and are considered by many authors to belong to a single genomic species [12]. Biochemically inactive, non-motile, lactose-negative *E. coli* (formerly the "Alkalescens-Dispar" group) can be misidentified as *Shigella* by automated phenotypic systems, and conversely [12]. Identification by automated systems should therefore be confirmed by slide agglutination with specific antisera, as recommended by the instrument in our case, and, where available, by MALDI-TOF mass spectrometry with appropriate databases or by molecular methods targeting markers such as *ipaH* [12]. Isolation of *Shigella* from any clinical specimen should also prompt notification and epidemiological investigation, given its very low infectious dose.

3.3 Antimicrobial resistance and therapeutic implications

Antimicrobial resistance in *Shigella* has increased dramatically over recent decades. Resistance to ampicillin, trimethoprim-sulfamethoxazole and, more recently, to fluoroquinolones, third-generation cephalosporins and azithromycin has been described worldwide, often associated with the international spread of multidrug-resistant lineages [1,14]. Fluoroquinolone resistance results mainly from mutations in the quinolone resistance-determining regions of *gyrA* and *parC*, sometimes combined with plasmid-mediated *qnr* genes [14]. Reflecting this threat, the World Health Organization has listed fluoroquinolone-resistant *Shigella* spp. among its high-priority pathogens in the 2024 Bacterial Priority Pathogens List [13].

Our isolate was resistant to both ciprofloxacin and levofloxacin, while remaining susceptible to the other antibiotic classes tested, including ampicillin and trimethoprim-sulfamethoxazole. This profile has direct clinical relevance: fluoroquinolones are widely used as empirical therapy for febrile UTI and for shigellosis, and our patient initially received a fluoroquinolone-based regimen. The concomitant aminoglycoside, to which the isolate was susceptible, probably provided effective coverage until the susceptibility results became available. This case illustrates that empirical treatment of UTIs, particularly in elderly patients, should always be reassessed in light of culture and susceptibility results, and that fluoroquinolones should not be relied upon for *Shigella* infections without susceptibility confirmation [1,13,14]. Third-generation cephalosporins, aminoglycosides or, in susceptible strains, trimethoprim-sulfamethoxazole represent appropriate options for febrile *Shigella* UTI, in line with the antibiotics successfully used in previously reported cases [8–11].

4 CONCLUSION

This case highlights that *Shigella boydii*, although rarely involved in extra-intestinal infections, can cause symptomatic febrile urinary tract infection, particularly in elderly patients with comorbidities. Clinical presentation is non-specific, so diagnosis relies on rigorous microbiological identification, including serological or molecular confirmation to distinguish *Shigella* from inactive *E. coli*. Systematic antimicrobial susceptibility testing is essential, as fluoroquinolone resistance may compromise empirical therapy. Further reports and surveillance studies are needed to better define the prevalence, risk factors and clinical implications of *Shigella* urinary tract infections.

STATEMENTS ON COMPLIANCE WITH ETHICAL STANDARDS

Acknowledgments

The authors thank the staff of the Laboratory of Microbiology of Avicenne Military Hospital, Marrakech.

Disclosure of conflict of interest

The authors declare no conflicts of interest.

Statement of informed consent

Written informed consent was obtained from the patient for the publication of this case report and the accompanying data.

Author contributions

H.K. conceived the report, collected the clinical and microbiological data and drafted the manuscript. J.B. contributed to the literature review and to drafting and revision of the manuscript. F.C. and Y.K. performed the microbiological analyses. L.A. supervised the work and critically revised the manuscript. All authors read and approved the final version.

REFERENCES

[1] Kotloff KL, Riddle MS, Platts-Mills JA, Pavlinac P, Zaidi AKM. Shigellosis. Lancet. 2018;391(10122):801–12. doi:10.1016/S0140-6736(17)33296-8.

[2] Anderson M, Sansonetti PJ, Marteyn BS. *Shigella* diversity and changing landscape: insights for the twenty-first century. Front Cell Infect Microbiol. 2016;6:45. doi:10.3389/fcimb.2016.00045.

[3] Kania DA, Hazen TH, Hossain A, Nataro JP, Rasko DA. Genome diversity of *Shigella boydii*. Pathog Dis. 2016;74(4):ftw027. doi:10.1093/femspd/ftw027.

[4] Barrett-Connor E, Connor JD. Extraintestinal manifestations of shigellosis. Am J Gastroenterol. 1970;53:234–45.

[5] Barrett-Connor E, Connor JD. *Shigella boydii* bacteremia. J Pediatr. 1969;75(2):298–300. doi:10.1016/s0022-3476(69)80402-6.

[6] Jao RL, Jackson GG. Asymptomatic urinary-tract infection with *Shigella sonnei* in a chronic fecal carrier. N Engl J Med. 1963;268:1165–8.

[7] Papasian CJ, Enna-Kifer S, Garrison B. Symptomatic *Shigella sonnei* urinary tract infection. J Clin Microbiol. 1995;33(8):2222–3. doi:10.1128/jcm.33.8.2222-2223.1995.

[8] Anatoliotaki M, Galanakis E, Tsekoura T, Schinaki A, Stefanaki S, Tsilimigaki A. Urinary tract infection caused by *Shigella sonnei*. Scand J Infect Dis. 2003;35(6–7):431–3.

[9] Baka S, Spathi A, Tsouma I, Kouskouni E. Symptomatic *Shigella sonnei* urinary tract infection in pregnancy. Clin Exp Obstet Gynecol. 2013;40(1):116–7.

[10] Karakaş A, Coşkun Ö, Kiliç A, Bedir O, Beşirbellioğlu BA. Urinary tract infections caused by *Shigella* species. Travel Med Infect Dis. 2016;14(2):167–9.

[11] Erdiren N, Çizmeci S, Şenel Ç, Kula Atik T. A case of urinary tract infection caused by *Shigella boydii*. Abant Med J. 2022;11(1):102–6. doi:10.47493/abantmedj.1033118.

[12] Devanga Ragupathi NK, Muthuirulandi Sethuvel DP, Inbanathan FY, Veeraraghavan B. Accurate differentiation of *Escherichia coli* and *Shigella* serogroups: challenges and strategies. New Microbes New Infect. 2018;21:58–62. doi:10.1016/j.nmni.2017.09.003.

[13] World Health Organization. WHO Bacterial Priority Pathogens List 2024: bacterial pathogens of public health importance to guide research, development and strategies to prevent and control antimicrobial resistance. Geneva: WHO; 2024.

[14] Baker S, The HC. Recent insights into *Shigella*. Curr Opin Infect Dis. 2018;31(5):449–54. doi:10.1097/QCO.0000000000000475.

[15] Flores-Mireles AL, Walker JN, Caparon M, Hultgren SJ. Urinary tract infections: epidemiology, mechanisms of infection and treatment options. Nat Rev Microbiol. 2015;13(5):269–84. doi:10.1038/nrmicro3432.